

Ochrobactrum anthropi Septic Arthritis of the Acromioclavicular Joint in an Immunocompetent 17 Year Old

TODD C. BATTAGLIA, MD, MS

Ochrobactrum anthropi is a ubiquitous, aerobic, gram-negative bacillus of low virulence, most frequently associated with nosocomial infections and infections related to indwelling catheters in immunocompromised hosts. This article presents the first reported case of *O anthropi* septic arthritis occurring at the acromioclavicular joint of an otherwise healthy patient and provides treatment recommendations based on our experience.

CASE REPORT

An otherwise healthy 17-year-old male was involved in a rollover tractor accident in which he jumped off the vehicle and landed directly on his right shoulder. He was initially seen in a local emergency department; radiographs were negative for fracture and dislocation, and he was discharged with the diagnosis of shoulder contusion. He also suffered a large superficial abrasion over the lateral and superior shoulder, but no lacerations or deep wounds. This healed uneventfully. Three months later, however, he presented to another physician with popping, catching, and pain in the superior shoulder. He reported that he had initially recovered by 2 weeks after the injury, but symptoms had progressed and he was now unable to raise his arm above his head without pain. He had experienced no fevers, chills, night sweats, or rash. According to the medical record, examination

at that time suggested bicipital tendonitis with no evidence of glenohumeral instability or rotator cuff injury. Examination of the acromioclavicular joint was not recorded. The initial radiographs were again reviewed as normal, and magnetic resonance imaging (MRI) was ordered. This demonstrated hypertrophy and inflammation at the acromioclavicular joint, with effusion, bony edema, and subcortical cystic changes at both the acromion and distal clavicle (Figure 1). No abscess or soft tissue mass was noted. The radiologist felt this was likely representative of erosive posttraumatic arthritis; however, infection could not “definitely be excluded.” The patient was then referred to the author for further care.

At the time of presentation to the author, 15 weeks after injury, the patient denied any systemic symptoms, including fevers, chills, or other joint pain. He was directly tender at the acromioclavicular joint, with exquisite pain on cross-body loading. There was no skin lesion, erythema, warmth, or other sign of infection. Rotator cuff and stability exams were normal, though impingement and apprehension tests caused pain directly at the acromioclavicular joint. Acromioclavicular joint injection versus distal clavicle excision were discussed; the patient opted for the former and the joint was injected with 80 mg of methylprednisolone and 8 cc of 0.5% lidocaine. This provided complete relief for 2 weeks, after which a gradual return to baseline pain occurred. The patient then

opted to proceed with surgery. Due to concern for possible infection, open rather than arthroscopic distal clavicle excision was offered. This was performed 5 months after the initial injury, with excision of 1 cm of distal clavicle, rasping of the medial acromion, culture of bone and soft tissue, and thorough joint irrigation. The distal clavicular fragment was also sent as a biopsy specimen. Intraoperative findings included thin but somewhat milky joint fluid without gross purulence. Postoperatively, the patient was placed on cephalexin pending culture results.

Bone and fluid cultures grew *O anthropi*, an organism for which our lab reported no validated susceptibility testing. Accordingly, input from the hospital’s infectious disease specialist was sought. Unfortunately, the specialist had little experience with this bacterium and offered no specific recommendations. The patient was placed on oral ciprofloxacin 500 mg twice daily for 4 weeks, as well as oral trimethoprim/sulfamethoxazole 160mg/800mg twice daily for 2 weeks. Postoperatively, he remained afebrile and the wound healed uneventfully. By 6 weeks after surgery, he had returned to all de-

Dr Battaglia is from Hess Orthopaedics and Sports Medicine, PLC, Harrisonburg, Virginia.

Dr Battaglia has no relevant financial relationships to disclose.

Correspondence should be addressed to: Todd C. Battaglia, MD, MS, Hess Orthopaedics and Sports Medicine, PLC, Harrisonburg, VA.

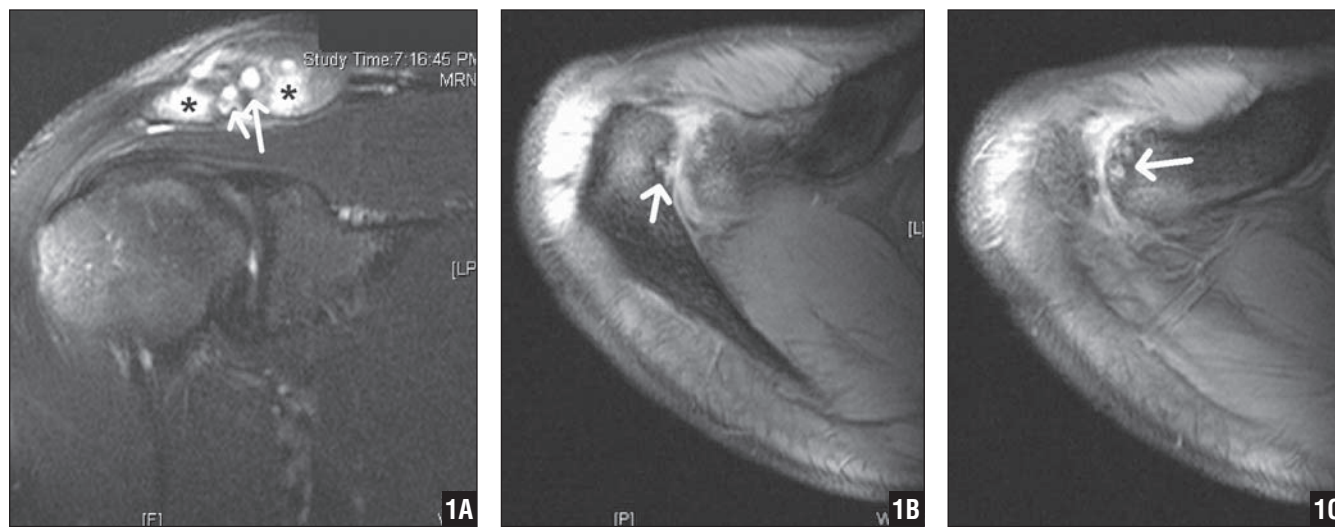


Figure 1: Coronal (A) and axial (B, C) T2-weighted MRI images demonstrating cystic erosions (white arrows) and edema (black stars) of the distal clavicle and medial acromion. Also note overall enlargement and increased fluid content of joint.

sired activities without pain. At 3- and 6-month follow-up, he reported no pain, and there was no tenderness at the acromioclavicular joint with full shoulder range of motion in all directions, symmetric with the nonoperative side. The incision was well healed with no erythema, and radiographs demonstrated no sign of further osteolysis or cystic change (Figure 2).

DISCUSSION

O anthropi is a gram-negative, aerobic, nonfermenting bacillus that is closely related to *Brucella* species.¹ It is ubiquitous in soil and aqueous environments, and is thought to be of relatively low virulence, most often acting as an opportunist pathogen in immunocompromised patients.^{1,2}

The first case of human infection with *O anthropi* was reported in 1980; since then, most reports have been associated with contamination of medical devices, including indwelling catheters, drains, and intravenous lines, especially in oncology patients.³⁻⁵ In addition to catheter-related infections, *O anthropi* has been reported as a cause of localized pyogenic infections, meningitis, endophthalmitis, endocarditis, and peritonitis.⁵ Occasionally, the bacterium has also been associated with serious, even life-threatening, infections in healthy hosts.^{2,6,7} Epidemic outbreaks, likely due to its ability to survive in water supplies, have also been described.³ In our patient, infection presumably occurred at the time of the initial accident, with inoculation occurring via a contaminated skin abrasion. Although this bacterium may be a contaminant in hospital environments, the presence of positive cultures on both the fluid and bone specimens makes contamination unlikely in our case.

To the best of our knowledge, this is the first reported case of septic arthritis due to *O anthropi*, although there were 2 previous reports of osteomyelitis due to the organism. One was a case of vertebral osteomyelitis; the other was associated with contaminated allograft tissue.^{5,8} In this case, clinical symptoms did not manifest for approximately 2

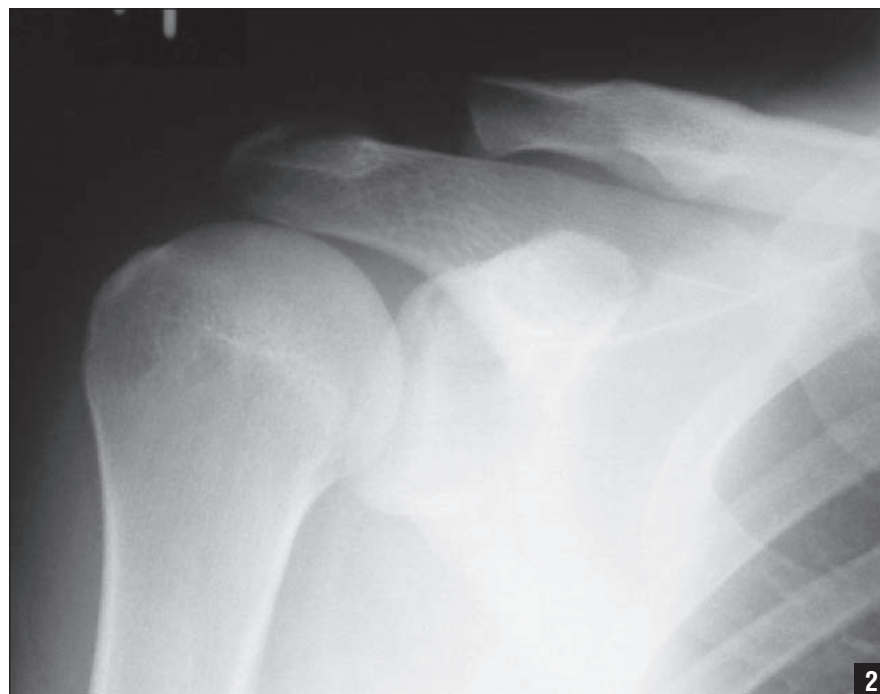


Figure 2: Three-month postoperative radiograph, demonstrating distal clavicle excision without evidence of further bony lysis or erosion.

weeks, and in this otherwise healthy host, no systemic symptoms were apparent at any time. Physicians should be aware that *O anthropi* may be a cause of septic arthritis, and that infection can occur in immunocompetent hosts, especially those with a history of accidental wounds. In retrospect, steroid injection in a case of possible infection was unwise, although erosive posttraumatic arthritis was the leading diagnosis at the time, and the potential risks were discussed beforehand with the patient. Although posttraumatic arthritis remained the leading diagnosis even after injection failed, infection remained on the differential, and open (rather than arthroscopic) surgical intervention was recommended to allow proper acquisition of culture specimens and adequate resection of pathologic bone.

The organism typically is resistant to penicillins and cephalosporins via production of inducible β -lactamase, and displays variable susceptibility to rifampicin, tetracyclines, trimethoprim, and

macrolides.^{5,9} Resistance may also be developing to sulfonamides. Though there is no standard established treatment, the literature describes susceptibility to aminoglycosides, carbapenems, quinolones, and cotrimoxazole.⁵ These reports typically recommend treatment of various durations with quinolones or dual antibiotic therapy. We elected treatment with a 2-week course of double agent therapy using ciprofloxacin and trimethoprim/sulfamethoxazole, with continuation of the quinolone for an additional 2 weeks. This regimen appears to have been effective, and we suggest its consideration in treatment of *O anthropi* septic arthritis.

REFERENCES

1. Arora U, Kaur S, Devi P. Ochrobactrum anthropi septicaemia. *Indian J Med Microbiol.* 2008; 26(1):81-83.
2. Galanakis E, Bitsori M, Samonis G, et al. Ochrobactrum anthropi bacteraemia in immunocompetent children. *Scand J Infect Dis.* 2002; 34(11):800-803.
3. Deliere E, Vu-Thien H, Levy V, Barguins S, Schlegel L, Bouvet A. Epidemiological investigation of Ochrobactrum anthropi strains isolated from a haematology unit. *J Hosp Infect.* 2000; 44(3):173-178.
4. Gransden WR, Eykyn SJ. Seven cases of bacteraemia due to Ochrobactrum anthropi. *Clin Infect Dis.* 1992; 15(6):1068-1069.
5. Wi YM, Sohn K, Rhee J, et al. Spontaneous bacterial peritonitis due to Ochrobactrum anthropi: a case report. *J Korean Med Sci.* 2007; 22(2):377-379.
6. Cieslak TJ, Robb ML, Drabick CJ, Fischer GW. Catheter-associated sepsis caused by Ochrobactrum anthropi: report of a case and review of related nonfermentative bacteria. *Clin Infect Dis.* 1992; 14(4):902-907.
7. Kettaneh A, Weill FX, Poilane I, et al. Septic shock caused by Ochrobactrum anthropi in an otherwise healthy host. *J Clin Microbiol.* 2003; 41(3):1339-1341.
8. Higgins CS, Avison MB, Jamieson L, Simm AM, Bennett PM, Walsh TR. Characterization, cloning and sequence analysis of the inducible Ochrobactrum anthropi AmpC beta-lactamase. *J Antimicrob Chemother.* 2001; 47(6):745-754.
9. Wheen L, Taylor S, Godfrey K. Vertebral osteomyelitis due to Ochrobactrum anthropi. *Intern Med J.* 2002; 32(8):426-428.